

## Isolated foveal hypoplasia without nystagmus: Imaging findings

Isolated foveal hypoplasia

Mehmet Barış Üçer<sup>1</sup>, Erdiñ Bozkurt<sup>2</sup>

<sup>1</sup>Department of Ophthalmology, Minister of Health Hitit University Erol Olçok Education and Research Hospital, Çorum,

<sup>2</sup>Department of Ophthalmology, Kafkas University Faculty of Medicine, Kars, Turkey

### Abstract

Foveal hypoplasia (FH) is commonly associated with other ocular anomalies as well as rarely as isolated. In this study, we reported the clinical features and imaging findings of an isolated FH without nystagmus. A 24-year-old female referred to the outpatient clinic complaining on non-progressive, mild visual impairment since early childhood without nystagmus. Spectral domain-optical coherence tomography (SD-OCT) revealed the absence of foveal depression in both eyes with continuity of all inner retinal layers. No capillary-free zone was observed in fluorescein angiography. In suspected cases, SD-OCT is a quick and non-invasive method for diagnosis but other imaging modalities may also helpful.

### Keywords

Isolated Foveal Hypoplasia; Nystagmus; Optical Coherence Tomography; Fluorescein Angiography

DOI: 10.4328/ACAM.6034 Received: 30.09.2018 Accepted: 06.11.2018 Publihed Online: 08.11.2018 Printed: 01.09.2019 Ann Clin Anal Med 2019;10(5): 634-6  
Corresponding Author: Mehmet Barış Üçer, Department of Ophthalmology, Minister of Health Hitit University, Erol Olçok Education and Research Hospital, Çorum, Turkey. T.: +90 3642193000 F.: +90 3642193030 E-Mail: dr.mbu@hotmail.com  
ORCID ID: <https://orcid.org/0000-0002-6807-4909>

## Introduction

Foveal hypoplasia (FH) is defined as the lack of foveal depression with continuity of all neurosensory retinal layers in the presumed foveal area [1]. Foveal hypoplasia has been described in association with several anatomical eye disorders, such as albinism, aniridia, achromatopsia, microphthalmia, retinopathy of prematurity and incontinentia pigmenti [1,2]. There is decreased visual acuity (VA) and an association with nystagmus in most cases of FH. However, only a few cases as an isolated anatomical finding without nystagmus have been reported [2,5]. Isolated FH is usually bilateral. However, unilateral cases have been reported in the literature [5,6]. In this study, we report a case of an isolated form of bilateral FH without nystagmus in which various imaging modalities were used to confirm the diagnosis.

## Case Report

A 24-year-old female referred to the outpatient clinic complaining on non-progressive mild visual impairment in both eyes since early childhood. Her familial and medical history were unremarkable. Her best-corrected VA for the right eye was 6/10 and the left eye was 7/10. She was able to read all the plates in the Ishihara's color vision test with each eye. Her extraocular movements were full, and she was orthophoric at distance and near. The intraocular pressures were 13 mmHg bilaterally and Humphrey visual field testing was normal. The pupils were round, equal, reactive and anterior chamber angle was normal with gonioscopy without evidence of aniridia (Figure 1). There was no nystagmus and no iris transillumination defects suggestive of ocular albinism and the iris was brown. The fundus examination revealed absent foveal reflexes in both eyes (Figure 2). The vitreous, papilla and retinal periphery were normal. No capillary-free zone was observed in the fluorescein angiography (FA), with the perifoveal capillaries running abnormally close to the presumed fovea and some of them crossing the horizontal meridian (Figure 3). Spectral Domain-Optical Coherence Tomography (SD-OCT) showed the absence of a foveal depression in both eyes with continuity of all inner retinal layers (Figure 4). Central foveal thickness was 266  $\mu\text{m}$  for the right eye and 264  $\mu\text{m}$  for the left eye.

## Discussion

The fovea is the most important retinal area for high VA and color vision. Morphologically, there are three important events in fovea maturation. At the first event, foveal depression starts to develop at 24-26 weeks of gestation with peripheral centrifugal migration of inner retinal layers. The foveal depression continues to deepen and is completed at 15 months after the birth. The other important events are centripetal migrations of cones and cone specialization. The outer nuclear layer widening occurs when centripetal migration of cone photoreceptors toward the location of the incipient fovea. Cone specialization begins at the same time in a concomitant process with cone migration: outer segment (OS) lengthening and thinning. Cone centripetal migration and OS lengthening lead to an increase in foveolar cone packing density [7,8].

Patients with FH can have a wide range of vision, from normal to severely impaired [9]. Our patient has mild visual impairment

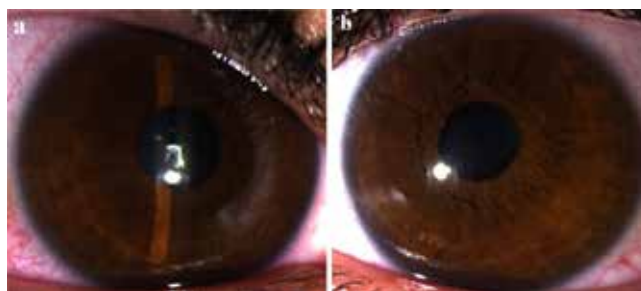


Figure 1. Anterior segment: Normal iris without transillumination (a: right eye, b: left eye)

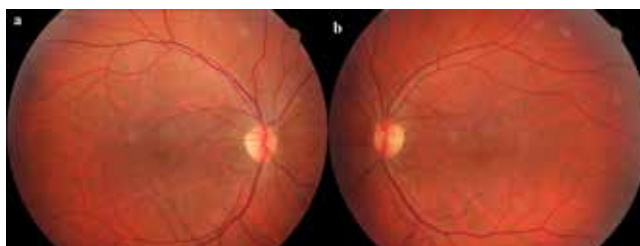

Figure 2. Colour Fundus Photo: Absence of foveal reflexes, retinal capillaries running abnormally close to presumed foveal areas, some of arterioles crossing the horizontal meridian (a: right eye, b: left eye)

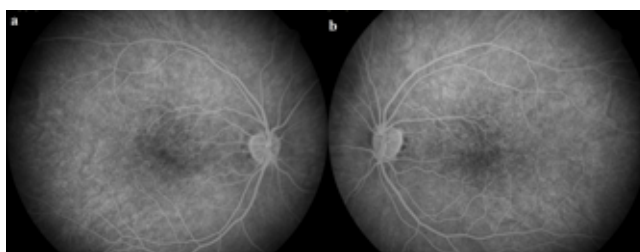


Figure 3. FA (late venous phase): An almost absent capillary-free zone, the perifoveal capillaries running abnormally close to the presumed foveal area (a: right eye, b: left eye)

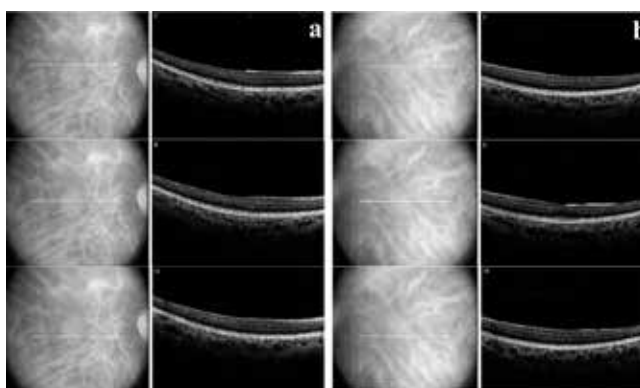


Figure 4. SD-OCT: Foveal hypoplasia characterized by the absence of extrusion of plexiform layers, absence of foveal depression and absence of OS lengthening (Grade 3 FH by Thomas et al. grading system). (a: right eye, b: left eye)

in both eyes. Charbel Issa et al. [10] suggested that VA in FH may be worse at low macular pigment density, therefore anatomical and functional integrity of macula correlates with pigment density. Marmor et al. [9] reported that foveal avascular zone (FAZ) and foveal depression were not critical to the postnatal cone lengthening and packing, that cone specialization could be maintained both anatomically and functionally. Thus, they have explained why some patients, such as the patient presented herein, may have a relatively good VA despite the absence of a normal foveal depression. Optical coherence tomog-

raphy angiography (OCTA) in eyes with FH showed an absence or severely reduced FAZ in the superficial capillary plexi but a small or partial FAZ area in the deep capillary plexi [5,11]. Bazvand et al. [5] have suggested that the size of the FAZ on OCTA could be correlated with visual potential. Pakzad-Vaezi et al. [11] reported that a small or partial FAZ in deep plexus permits no resistance to continued centripetal cone migration and specialization resulting in intact vision. Thomas et al. [8] identified four grades of FH with using SD-OCT scans based on the extrusion of foveal plexiform layers, the presence of foveal depression, photoreceptor OS lengthening and widening of the outer nuclear layer. There was a significant relationship between VA and the grade of hypoplasia. Increasing grades of FH was correlated with worsening VA. They have suggested that the grading system is a prognostic indicator for VA. Furthermore, this grading system is important to show in which stage foveal development is arrested. Both eyes of our patient conform to FH properties of grade 3 according to this classification.

Various imaging systems are available for assessing the foveal region. Fluorescein angiography is one of the imaging modalities that can be used in suspected FH cases. On the imaging findings of FH in FA there is absence of FAZ, capillaries running abnormally close to the presumed fovea and some of them crossing the horizontal meridian, variable choroidal fluorescence due to macular pigment density [2,4,12]. It is not one of the primary methods preferred in making diagnosis because of being invasive, having a time limitation of 5-10 minutes after contrast practices, evaluating only retinal superficial capillaries and practical difficulties on children [13]. Nowadays, SD-OCT is used as a non-invasive and quick method to confirm the diagnosis of suspected FH. In addition, thanks to the high-resolution images, the arrested stage of foveal development can be demonstrated by evaluating the retinal layers and morphology. Another advantage is that it can be used not only in adults but also in pediatric age groups [13].

In conclusion, we report on a 24-year-old female with isolated FH, who has bilateral mild visual impairment without nystagmus or any ocular anomaly. Isolated FH is rare, therefore, should be considered in the differential diagnosis of visual impairment when foveal reflex is not observed. In suspected cases, SD-OCT is a quick and non-invasive method for the diagnosis. It is extremely useful but other imaging modalities may also help to diagnose.

#### **Scientific Responsibility Statement**

*The authors declare that they are responsible for the article's scientific content including study design, data collection, analysis and interpretation, writing, some of the main line, or all of the preparation and scientific review of the contents and approval of the final version of the article.*

#### **Animal and human rights statement**

*All procedures performed in this study were in accordance with the ethical standards of the institutional and/or national research committee and with the 1964 Helsinki declaration and its later amendments or comparable ethical standards. No animal or human studies were carried out by the authors for this article.*

#### **Conflict of interest**

*None of the authors received any type of financial support that could be considered potential conflict of interest regarding the manuscript or its submission.*

#### **References**

1. Recchia FM, Carvalho-Recchia CA, Trese MT. Optical coherence tomography in the diagnosis of foveal hypoplasia. *Arch Ophthalmol.* 2002; 120(11):1587-8.
2. Querques G, Prascina F, Iaculli C, Delle Noci N. Isolated foveal hypoplasia. *Int Ophthalmol.* 2009; 29(4):271-4.
3. Karaca EE, Çubuk MÖ, Ekici F, Akçam HT, Waisbourd M, Hasanreisioğlu M. Isolated foveal hypoplasia: clinical presentation and imaging findings. *Optom Vis Sci.* 2014; 91: 61-5.
4. Batioğlu F, Demirel S, Özmert E, Bayraktar B, Yanık Ö. The Diagnostic Role of Multimodal Imaging Techniques in Isolated Foveal Hypoplasia. *Turk J Ophthalmol.* 2017; 47(5):306-8.
5. Bazvand F, Karkhaneh R, Roohipoor R, Rajabi MB, Ebrahimiadib N, Davoudi S, et al. Optical Coherence Tomography Angiography in Foveal Hypoplasia. *Ophthalmic Surg Lasers Imaging Retina.* 2016; 47(12):1127-31.
6. Iqbal MM, Makar I. Unilateral isolated foveal hypoplasia. *Can J Ophthalmol.* 2018; 53(3):107-9.
7. Yuodelis C, Hendrickson A. A qualitative and quantitative analysis of the human fovea during development. *Vision Res.* 1986; 26(6):847-55.
8. Thomas MG, Kumar A, Mohammad S, Proudlock FA, Engle EC, Andrews C, et al. Structural grading of foveal hypoplasia using spectral-domain optical coherence tomography a predictor of visual acuity? *Ophthalmology.* 2011; 118(8):1653-60.
9. Marmor MF, Choi SS, Zawadzki RJ, Werner JS. Visual insignificance of the foveal pit: reassessment of foveal hypoplasia as fovea plana. *Arch Ophthalmol.* 2008; 126(7):907-13.
10. Charbel Issa P, Foerl M, Helb HM, Scholl HP, Holz FG. Multimodal fundus imaging in foveal hypoplasia: combined scanning laser ophthalmoscope imaging and spectral-domain optical coherence tomography. *Arch Ophthalmol.* 2008; 126(10):1463-5.
11. Pakzad-Vaezi K, Keane PA, Cardoso JN, Egan C, Tufail A. Optical coherence tomography angiography of foveal hypoplasia. *Br J Ophthalmol.* 2017; 101(7):985-88.
12. Oliver MD, Dotan SA, Chemke J, Abraham FA. Isolated foveal hypoplasia. *Br J Ophthalmol.* 1987; 71(12):926-30.
13. Holmstrom G, Eriksson U, Hellgren K, Larsson E. Optical coherence tomography is helpful in the diagnosis of foveal hypoplasia. *Acta Ophthalmol.* 2010; 88(4):439-42.

#### **How to cite this article:**

*Üçer MB, Bozkurt E. Isolated foveal hypoplasia without nystagmus: Imaging findings. Ann Clin Anal Med 2019;10(5): 634-6.*